

CASE REPORT

NECROTIZING FASCIITIS SECONDARY TO TUBERCULOSIS IN A MIDDLE-AGED MAN

Radha Verma¹, Amiti Shah², Kiran Gaikwad³, Zaffar Karam Sayed⁴, Priyesh S. Halgaonkar⁵

HOW TO CITE THIS ARTICLE:

Radha Verma, Amiti Shah, Kiran Gaikwad, Zaffar Karam Sayed, Priyesh S. Halgaonkar. "Necrotizing Fasciitis Secondary to Tuberculosis in a Middle-Aged Man". Journal of Evolution of Medical and Dental Sciences 2014; Vol. 3, Issue 24, June 16; Page: 6675-6678, DOI: 10.14260/jemds/2014/2802

ABSTRACT: Necrotizing fasciitis is a life-threatening soft tissue infection that results in rapid local tissue destruction. Type 1 necrotizing fasciitis is characterized by polymicrobial, synergistic infections that are caused by non-Group A Streptococci, aerobic and anaerobic organisms. Type 2 necrotizing fasciitis involves Group A Streptococcus (GAS) with or without a coexisting staphylococcal infection. If not treated precociously and in an adequate manner the mortality rate can reach up to 74%.^[1] Here we present a case of 37years old male with tuberculous necrotising fasciitis presenting with signs of acute inflammation. The tissue was debrided (sent for histopathological examination) and pus drained (sent for routine culture and AFB culture). The histopathological report of the underlying muscle and fascia was suggestive of tuberculous inflammation (dense neutrophilic infiltration with caseous necrosis) while the pus culture and AFB culture was negative for Mycobacterium species.

KEYWORDS: Necrotizing fasciitis, tuberculosis, neutrophilic infiltration, caseous necrosis.

INTRODUCTION: Necrotizing fasciitis, commonly known as "flesh eating disease" has received different denominations: progressive bacterial synergistic gangrene, Meleneys' Gangrene, Fourniers', etc., is an infection of the subcutaneous tissue and deep fascia. It is a life threatening surgical emergency characterized by rapidly spreading necrosis of the subcutaneous fat and fascia with thrombosis of cutaneous micro-circulation.^[2-3] Although the syndrome of necrotizing fasciitis was originally described by Pare in sixteenth century, the term necrotizing fasciitis was first used by Wilson in 1952.^[4]

It is usually caused by virulent organisms of the streptococcus genus, anaerobic bacteria or enterobacteria. Though the incidence of tuberculosis infection in patients with systemic illness is around 3%,^[5] presentation as necrotizing fasciitis is exceptional. The diagnosis of this rare complication requires a high suspicion index and the demonstration of Mycobacterium tuberculosis in the tissue, due to the fact that the symptoms can imitate even the underlying pathology and should be suspected in patients with necrotizing fasciitis with recurrence or unexpected slow response to surgery. Clinical signs include oedema stretching beyond visible skin erythema, woody hard texture of subcutaneous tissue, pronounced tenderness, fever, tachycardia, subcutaneous gas and soft tissue crepitus.^[6] Treatment includes early surgical debridement, parenteral antibiotics and nutritional support.

CASE REPORT: We present the case of a 39 years old male, an old case of pulmonary tuberculosis who presented to us with 5-day history of fever, malaise, anorexia, weakness, swelling over right lower limb, pain in right hip joint, severe pain in the right inguinal, medial side of right thigh, left inguinal region and scrotum.

CASE REPORT

On physical examination patient had temperature of 38.5°C, pulse of 102bpm and blood pressure of 120/70 mmHg and tachypneic. Tender erythematous indurated swelling was seen in the right side inguinal region of about 10cms in diameter with diffuse margin along with skin excoriation and induration extending from anterior abdominal wall from umbilicus to mid-thigh level in vertical extent and horizontally extending from anterior superior iliac spine to medial aspect of thigh with involvement of scrotal skin. Left sided inguinal region had some superficial necrotic patch along with induration.

Multiple right superficial inguinal lymph nodes were palpable. Peripheral arterial pulsations were normal and symmetric. No sensory deficit was found. Bilateral hip movements were restricted and painful. The complete blood count revealed hemoglobin 10.5 gm/dl; total white blood cells 7100 cells/ μ l; platelets 94000/ μ l; ESR 56 mm at the end of 1st hour. Rest of the blood investigations including serum Creatinine, electrolytes, blood urea, liver function tests were within normal limits. Human immunodeficiency virus (HIV), hepatitis B virus (HBsAg) and antinuclear antibodies were negative. Our patient had history of pulmonary tuberculosis in 2010 for which he took one year of anti-tuberculosis drugs and had stopped them after being sputum negative for tuberculosis. Chest X-ray was suggestive of bilateral pulmonary infiltration with pleural thickening and calcification.

The patient was immediately taken to the operating room to undergo radical debridement.

The pus drained was sent for culture and tissue excised was sent for histopathological examination. The patient was started on broad spectrum antibiotics as piperacillin and tazobactam, but the patient's condition did not improve and was taken for repeated debridement. The histopathological report was suggestive of tuberculous inflammation and the patient was started on anti-tubercular drugs and the patient's general condition as well as wound started improving dramatically. Once the wound was healthy with good granulation tissue, skin grafting of his right groin wound and primary closure of right thigh wound and left inguinal wound was done.

DISCUSSION: Necrotizing fasciitis [NF] is a serious life threatening soft tissue infection resulting in rapid local tissue destruction characterized by liquefactive necrosis and angiothrombotic microbial invasion^[1]. As described earlier type 1 and type 2 NF have similar clinical manifestations but affect different subgroup of patients, type 1 tends to affect diabetic and immunocompromised while type 2 tends to occur in individuals with no underlying co-morbidity.^[1] The most common presentation are swelling (94%), pain (85%) and erythema (77%). Also seen are skin necrosis, crepitus and bullae. NF typically affects the extremities but sometimes is seen on face, perineum and other parts of body.^[7]

There is no sex predilection for NF and occurs more frequently in immunocompromised patients, intravenous drug users, alcoholics, renal or liver diseases, diabetics and patients with peripheral vascular diseases. NF can be the initial presentation of tuberculosis in rare cases^[8]. Initially constitutional symptoms of tuberculosis including low-grade fever, anorexia and weight loss may be absent.^[9] Tuberculous NF is established in presence of polymorphonuclear infiltrate with muscle fascia necrosis and the isolation of M. Tuberculosis in the tissue.

The diagnosis of NF is based on surgical exploration or the anatomopathologic study of the subcutaneous tissue. Imaging studies are useful in evaluation of extension and local complications. The start of anti-tubercular treatment is generally delayed owing to high degree of suspicion of the surgeon and the conventional cultures being negative.

CASE REPORT

Patients that die due to tuberculous fasciitis are generally immunocompromised, delay in starting treatment and multiple muscle groups affected.^[10] The mainstay of treatment of NF is emergent surgical debridement, broad spectrum IV antibiotics after initial resuscitation with fluid and electrolyte replacement and/or blood transfusion.^[11] According to Wipf et al the single most important determinant of survival is the amount of time elapsed between initial presentation and surgical debridement.^[11]

Our patient when started on anti-tubercular treatment showed dramatic improvement, both the general and local symptoms and was discharged after skin grafting and wound closure.

CONCLUSION: Necrotizing fasciitis is rapidly progressive extensive necrosis of subcutaneous fat and fascia; is more common in middle aged males. Findings at surgical exploration and skin biopsy are reliable methods of diagnosis. Treatment includes early and adequate surgical debridement, parenteral antibiotics and nutritional support. The diagnosis of tuberculosis should be suspected in patients of NF with recurrence or delayed response to treatment.

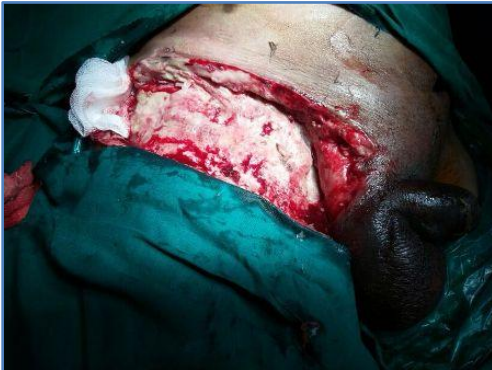

Fig. 1: Wound after first debridement

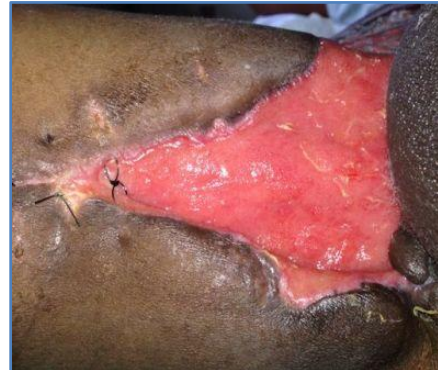


Fig. 2: Wound after repeated debridement

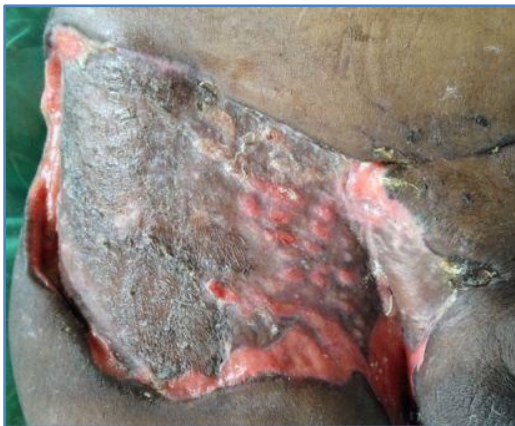

Fig. 3: Wound after skin grafting

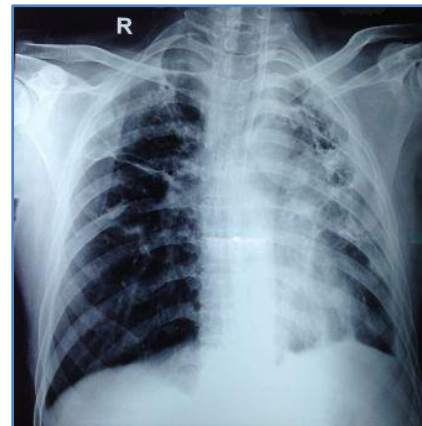


Fig. 4: Chest X-ray

CASE REPORT

REFERENCES:

1. Wong C, Chnag HC, Pasupathy S, Khin LW, Tan JL, Low CO. Necrotizing fasciitis: clinical presentation, microbiology, and determinants of mortality. *J Bone Joint Sur.* 2003; 85-A: 1454-60.
2. Shaikh N. Necrotizing fasciitis: A decade of surgical intensive care experience. *Indian J Crit Care Med* 2006; 10: 225-9.
3. Kandil A. Necrotizing fasciitis: Study of 20 cases in Shifa Hospital. *Palestine Medical Journal* 2006; 2 (3): 16-21.
4. Hamad H, Al Mosleh A/W, Al Maslamani Y, Abu Nada M, Al Harami M. The outcome of surgical management of necrotizing fasciitis in Qatar: 8 years results. *The Middle East Journal of Emergency Medicine.* 2001; 1(1): 3-4
5. Chan AT, Cleeve V, Daymond TJ. Necrotising fasciitis in a patient receiving infliximab for rheumatoid arthritis. *Postgrad Med J.* 2002; 78: 47-8.
6. C. H. Wong, H. C. Chang, S. Pasupathy, L. W. Khin, J. L. Tan, and C. O. Low, "Necrotizing fasciitis: clinical presentation, microbiology, and determinants of mortality," *Journal of Bone and Joint Surgery—Series A*, vol. 85, no. 8, pp. 1454–1460, 2003.
7. Hill MK, Sanders CV. Skin and soft tissue infections in critical care. *Crit Care Clin* 1998;14 (2): 251-62.
8. Stebbings AE, Ti TY, Tan WC. Necrotizing fasciitis--an unusual presentation of miliary mycobacterium tuberculosis. *Singapore Med J* 1997; 38: 384-5.
9. Lakhanpal S, Linscheid RL, Ferguson RH, Ginsburg WW. Tuberculous fasciitis with tenosynovitis. *J Rheumatol* 1987; 14: 621-4.
10. Wang JY, Lee LN, Hsueh PR, Shih, JY, Chang YL, Yang PC, et al. Tuberculous myositis: a rare but existing clinical entity. *Rheumatology.* 2003; 42: 836-40.
11. Wipf SAM, Greenhagen RM, Mandi DM, Bevilacqua NJ, Rogers LC. Necrotizing Soft Tissue Infection of the Foot: A Case Report. *The Foot and Ankle Journal* 2008; 1(4): 2.

AUTHORS:

1. Radha Verma
2. Amiti Shah
3. Kiran Gaikwad
4. Zaffar Karam Sayed
5. Priyesh S. Halgaonkar

PARTICULARS OF CONTRIBUTORS:

1. Professor and Head of Unit, Department of Surgery, KJSMC, Mumbai, India.
2. Lecturer, Department of Plastic Surgery, KJSMC, Mumbai, India.
3. Assistant Professor, Department of Surgery, KJSMC, Mumbai, India.
4. Resident, Department of Surgery, KJSMC, Mumbai, India.

5. Resident, Department of Surgery, KJSMC, Mumbai, India.

NAME ADDRESS EMAIL ID OF THE CORRESPONDING AUTHOR:

Dr. Radha Verma,
OPD 3, K. J. Somaiya Medical College,
Everard Nagar, Near Eastern Express Highway,
Sion, Mumbai, India.
E-mail: drradha.verma@gmail.com

Date of Submission: 02/06/2014.

Date of Peer Review: 03/06/2014.

Date of Acceptance: 09/06/2014.

Date of Publishing: 13/06/2014.